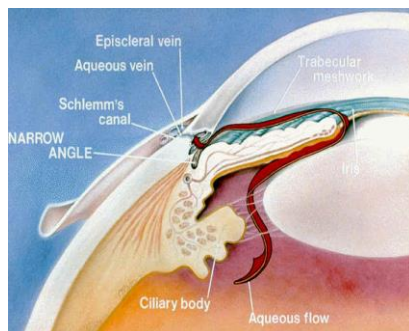


## Angle-Closure Glaucoma (ACG)

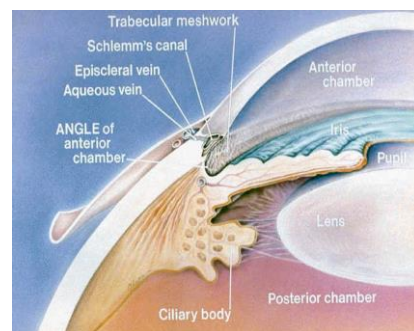
In a normal eye, fluid is constantly produced and drained at a balanced rate through the trabecular meshwork, positioned at the front of the eye in the corner or angle of a space called the anterior chamber.

In an eye with narrow angles, the fluid is obstructed from reaching the angle because the angle becomes blocked by part of the iris (the coloured part of the eye). This is like putting a stopper over the drain of a sink. If the iris completely blocks the drainage, the pressure becomes extremely high.

### Glaucoma - Narrow Angles



### Glaucoma – Open Angles



There are different types and grades of ACG:

- **Narrow angles:** These people are at risk for developing ACG. They can be identified using a special examination technique called gonioscopy. This involves placing a contact lens on the eye in order to examine the angle of the eye.
- **Intermittent angle closure:** These people have a series of minor attacks when the angle becomes partially or intermittently blocked.
- **Acute angle closure:** This results in a sudden increase in pressure and is an emergency. The eye can become very painful and red. If the pressure rises high enough, the pain may become so intense that it can cause nausea and vomiting. The cornea swells and clouds, and the patient may see haloes around lights and experience blurred vision. Permanent loss of vision or blindness may result.
- **Chronic angle closure:** This is when the closure of the drainage system occurs gradually. Symptoms do not occur until the angle is almost completely closed over.

**People at risk include:** Hyperopes (far-sighted), elderly, family history of ACG, Asians

**Treatment:** The treatment usually involves a combination of eye drops and/or a laser procedure known as laser peripheral iridotomy. With the laser a small opening is made in the iris allowing fluid to pass directly to the anterior chamber, releasing the build-up of pressure behind the iris.

Even if the iris can be taken out of the drainage gutter successfully, the trabecular meshwork is injured and may not work as well ever again. This is why after successful laser operations it may be necessary to maintain a patient on pressure lowering medications or even do a drainage operation.