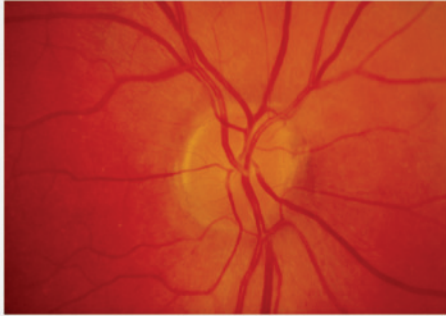
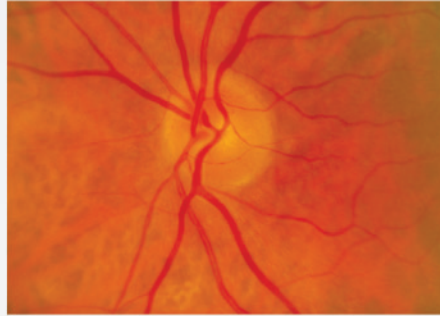


Optic Nerve Head Signs in Glaucoma

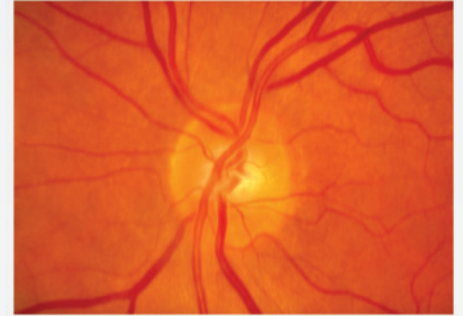
Diffuse Cupping - Vertical Cup:Disc Ratio (VCDR)



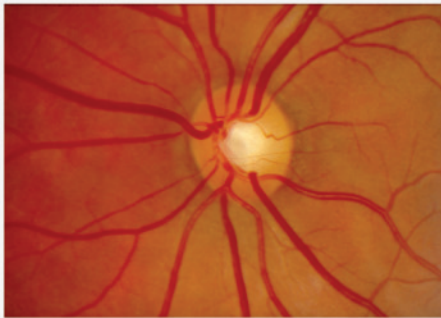
VCDR 0.0



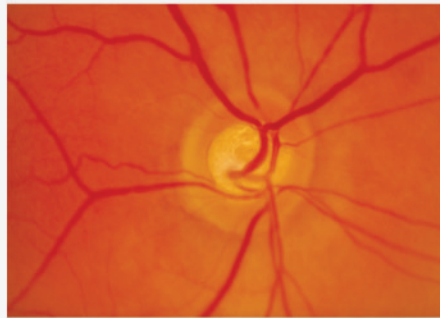
VCDR 0.2



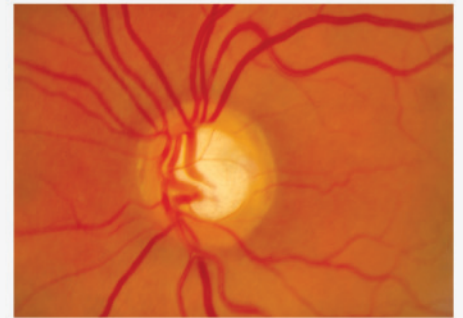
VCDR 0.4



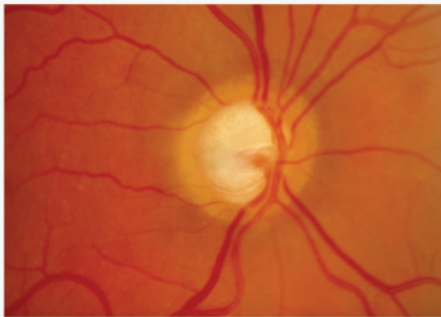
VCDR 0.5



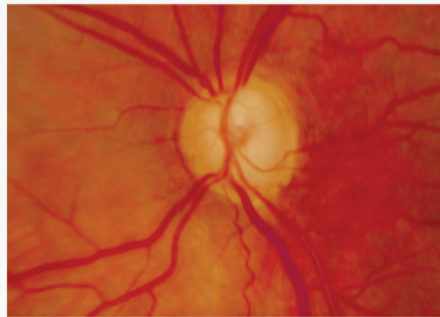
VCDR 0.6



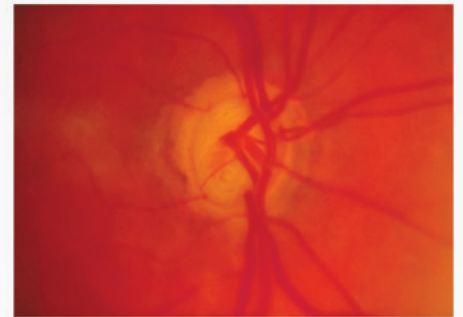
VCDR 0.7



VCDR 0.8

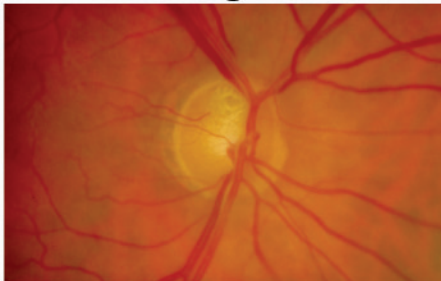


VCDR 0.9

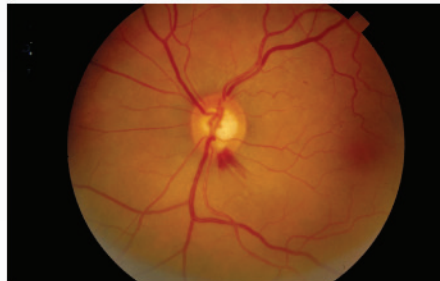


VCDR 1.0

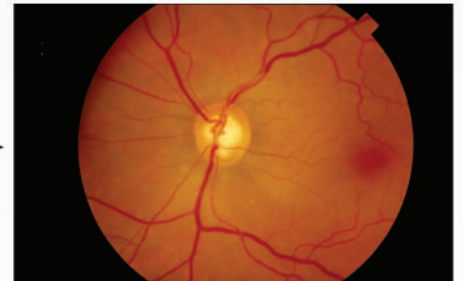
Focal Damage



Vertical Notch



Disc Margin Haemorrhage



Nerve Fibre Layer Defect

Consider:

Disc Size

Age

Neural Rim Pallor

Family History

Bilateral Symmetry

Myopia